

PATIENT PRESENTING CLINICAL SIGNS

Samantha Anderson Pt has had chronic diarrhea for the past couple of month. Medication trials were performed but prednisone was the only medication that had a positive response. When patient was on prednisone, the diarrhea stopped & stools were soft but shaped but the diarrhea will be present once prednisone was taper off. Rocks in the stomach was an incidental finding.

SPECIES

Canine

COMPUTED TOMOGRAPHIC STUDY OF THE ABDOMEN

Plain and post contrast studies are available for review.

BREED

Pitbull Mix

COMPUTED TOMOGRAPHIC FINDINGS

The serosal fat presents normal attenuation behavior. There is no evidence of peritoneal effusion or peritonitis.

SEX

FS

Both kidneys present within normal limits for size, shape and organ architecture. After contrast administration, a bilaterally symmetric and uniform nephro- and pyelogram is noted.

The adrenal glands are within normal limits for size, shape and organ architecture.

AGE

11yr

The liver presents with normal shape, even surface, uniformly attenuating parenchyma and homogeneous contrast enhancement, unremarkable. The gallbladder is moderately distended. A moderate amount of mineral sediment with mild gallbladder wall thickening and small mineralizations adhering to the wall is seen.

INTERPRETED BY

Nele Eley (Ondreka),
DVM Dr. med. vet.,
DipECVDI

The pancreas is evenly contoured, the pancreatic parenchyma is homogeneous and presents uniform contrast enhancement.

There is no evidence of mesenteric lymphadenomegaly.

HOSPITAL NAME

CARE Surgery Center

Multiple intraluminal stomach concretions up to 2.5 cm in size are seen. There is no evidence of obstruction. None of the stones has passed into the small intestine. The small intestine presents mild generalized wall thickening of ~ 4 mm wall thickness throughout. No discrete mass or obstruction is identified.

REFERRING VET

Samantha Parkinson

A small hyperenhancing splenic nodule is seen.

INVOICE

23917

COMPUTED TOMOGRAPHIC DIAGNOSIS

- Mild diffuse small intestinal wall thickening: suspect chronic enteropathy
- Ingestion of multiple stones in stomach up to 2.5 cm in size, may require monitoring or removal if clinical signs occur
- Gallbladder mineralization and wall thickening: suspect chronic cholecystitis, no obstruction noted at this time
- Small splenic nodule

DATE

02/18/2026

INTERPRETATION OF FINDINGS & FURTHER RECOMMENDATIONS



PATIENT

Samantha Anderson

The diffuse small intestinal wall thickening correlates with the history of steroid responsive chronic diarrhea. Inflammatory bowel disease or chronic enteropathy are primary differential diagnoses. Early round cell infiltrate can never be completely excluded but is considered by far less likely.

SPECIES

Canine

The stones in the stomach may be incidental. However, they may become clinically relevant if obstruction or vomiting develops.

Consider the possibility of low grade chronic cholecystitis.

No significant lymphadenopathy is seen at this point.

BREED

Pitbull Mix

SEX

FS

AGE

11yr

INTERPRETED BY

Nele Eley (Ondreka),
DVM Dr. med. vet.,
DipECVDI

HOSPITAL NAME

CARE Surgery Center

REFERRING VET

Samantha Parkinson

INVOICE

23917

DATE

02/18/2026



PATIENT

Samantha Anderson

SPECIES

Canine

BREED

Pitbull Mix

SEX

FS

AGE

11yr

INTERPRETED BY

Nele Eley (Ondreka),
DVM Dr. med. vet.,
DipECVDI

HOSPITAL NAME

CARE Surgery Center

REFERRING VET

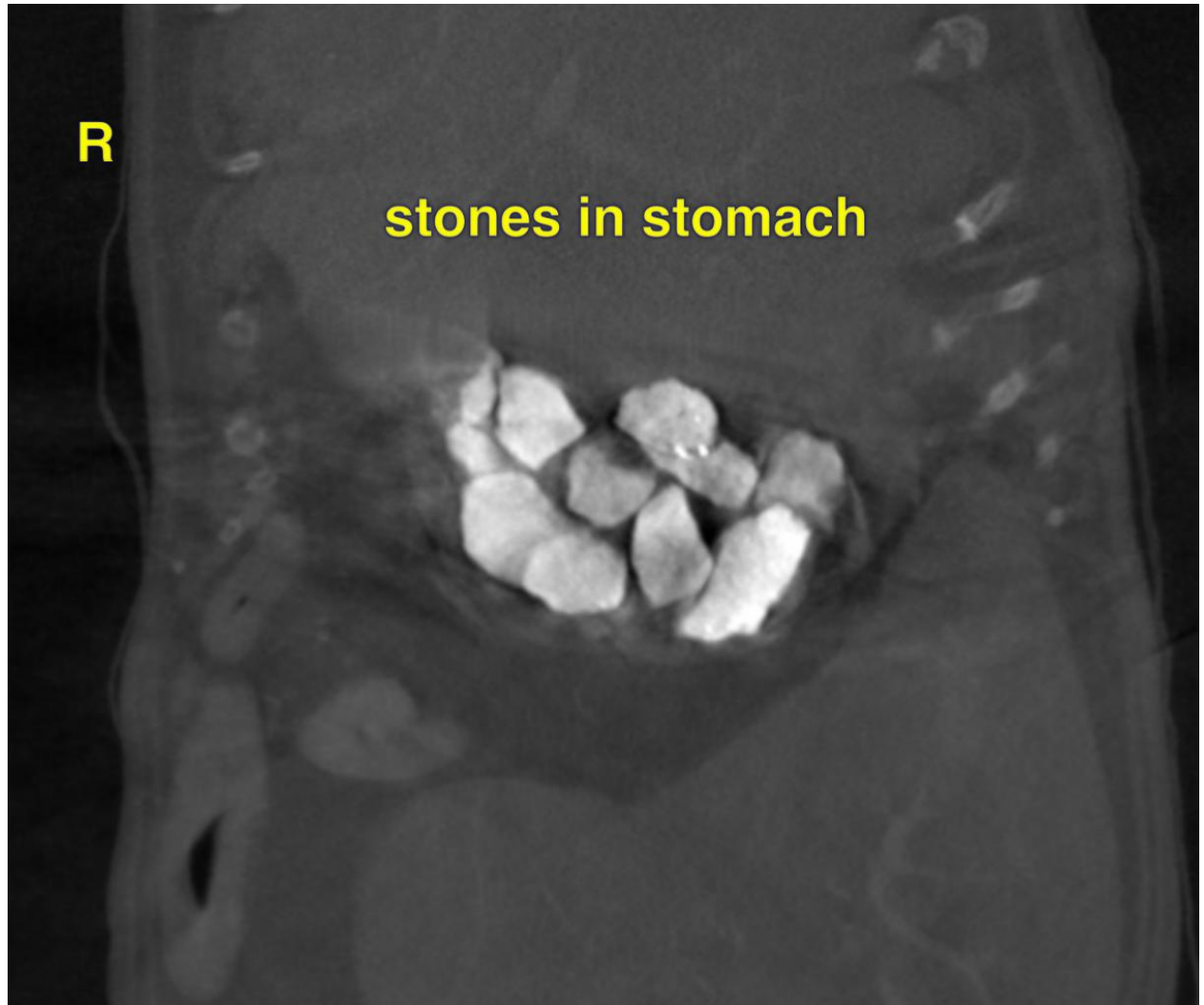Samantha Parkinson

INVOICE

23917

DATE

02/18/2026





PATIENT

Samantha Anderson

SPECIES

Canine

BREED

Pitbull Mix

SEX

FS

AGE

11yr

INTERPRETED BY

Nele Eley (Ondreka),
DVM Dr. med. vet.,
DipECVDI

HOSPITAL NAME

CARE Surgery Center

REFERRING VET


Samantha Parkinson

INVOICE

23917

DATE

02/18/2026





PATIENT

Samantha Anderson

SPECIES

Canine

BREED

Pitbull Mix

SEX

FS

AGE

11yr

INTERPRETED BY

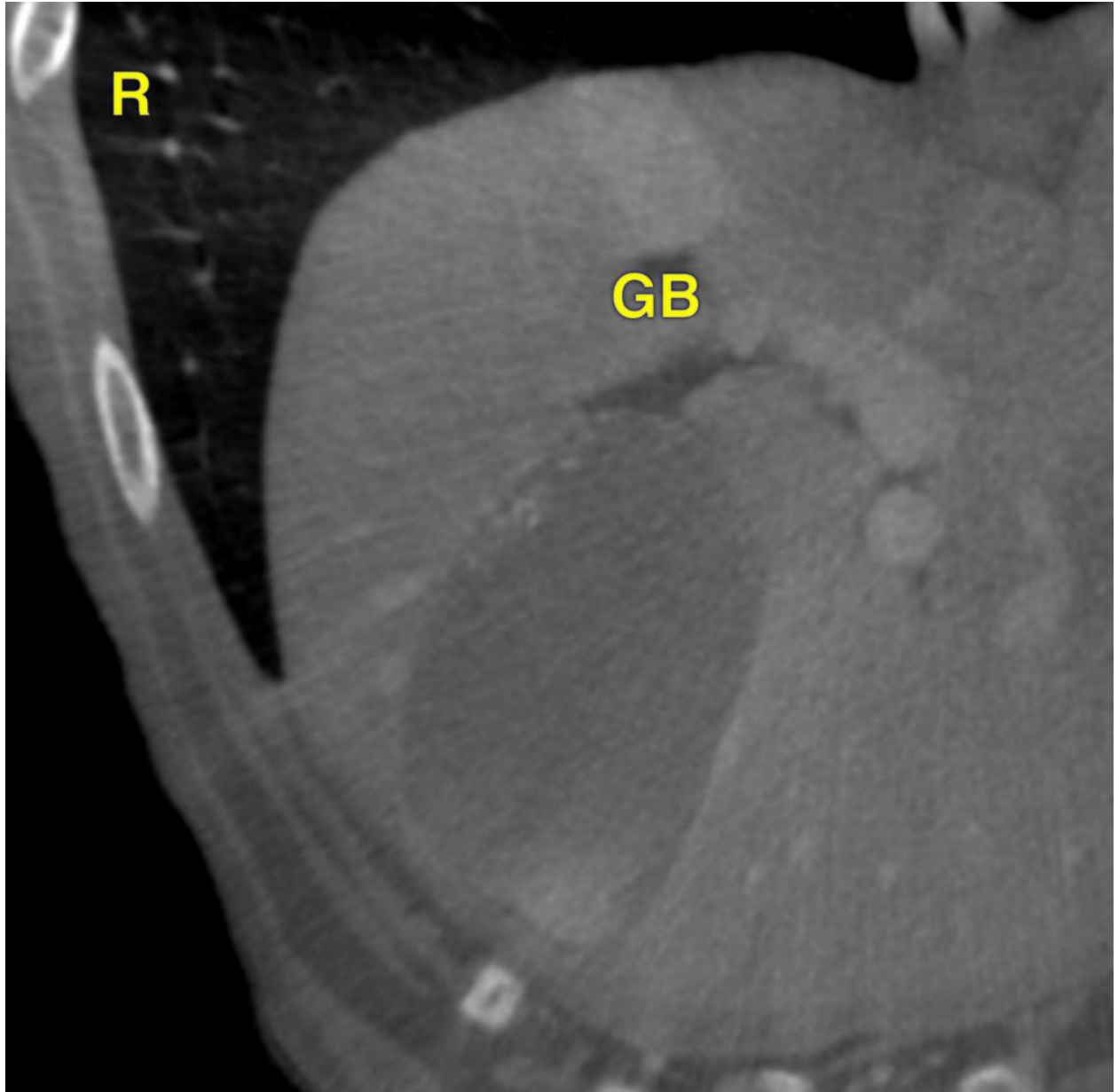Nele Eley (Ondreka),
DVM Dr. med. vet.,
DipECVDI

HOSPITAL NAME

CARE Surgery Center

REFERRING VET

Samantha Parkinson

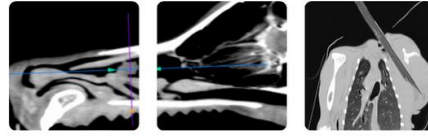


INVOICE

23917

DATE

02/18/2026



PATIENT

Samantha Anderson

The information and recommendations provided are based on the images presented by the referring veterinarian. No evaluation can be communicated regarding pathology that was not visible in the image/video clips provided.

SPECIES

Canine

Thank you for this referral. If the clinical or image interpretation does not parallel your findings or if I can be of any further assistance please contact me.

BREED

Pitbull Mix

Nele Eley (Ondreka), DVM, Dr. med. vet., DipECVDI
European Specialist in Veterinary Diagnostic Imaging, Cert. Radiology,
Senior lecturer University of Giessen/Germany, Veterinary Faculty, Department of Radiology.
info@sonopath.com

SEX

FS

AGE

11yr

INTERPRETED BY

Nele Eley (Ondreka),
DVM Dr. med. vet.,
DipECVDI

HOSPITAL NAME

CARE Surgery Center

REFERRING VET

Samantha Parkinson

INVOICE

23917

DATE

02/18/2026